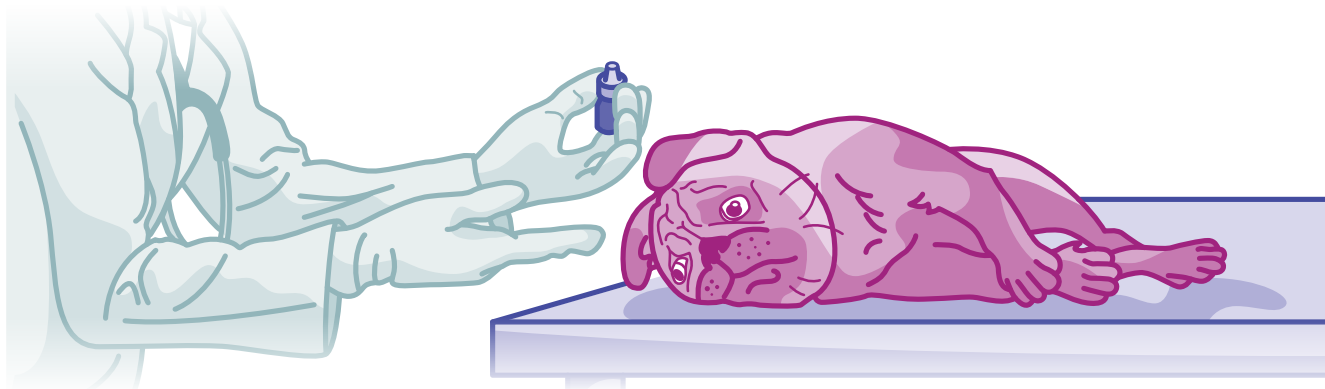


CLAIM OF THE MONTH

CORNEAL ULCER AND ENTROPION

Pet: Jack*, 7-month-old male Pug



JACK'S STORY:

Jack the pug started to have discharge from his eyes late one week. By the weekend, he was squinting and his eyes looked painful and swollen.

When he was examined, the vet found that the left eye was red and watering. The surface of the eye appeared wounded: it was cloudy and absorbed a special stain used to detect eye injuries. His vet diagnosed a superficial corneal ulcer – the traumatic loss of part of the surface layer of the eye. He was prescribed antibiotic eye drops to treat and prevent infection and additional eye drops to provide lubrication and treat pain.

At first, Jack's eye seemed to improve, but after two days of treatment, things got worse. Jack started rubbing and scratching his eye, and there was more redness, squinting and swelling. The vet prescribed additional pain medications and a cone collar. Unfortunately, the ulcer didn't respond to treatment. The infection worsened and caused the defect to become deeper, threatening the eye. A decision was made to refer Jack to a veterinary ophthalmologist.

The ophthalmologist determined that the eye was at risk for rupturing. He discovered the ulcer was likely caused by entropion – a condition where the lower eyelids roll inwards, causing the hair on the lid to repeatedly brush against the surface of the eye.

ABOUT THE CONDITION: CORNEAL ULCERATION

The cornea is the crystal-clear tissue that we see at the front of the eye. It is made of a waterproof layer of cells on the surface and several transparent layers of cells underneath. A membrane is found at the deepest layer, separating the cornea from the liquid anterior chamber of the eye.

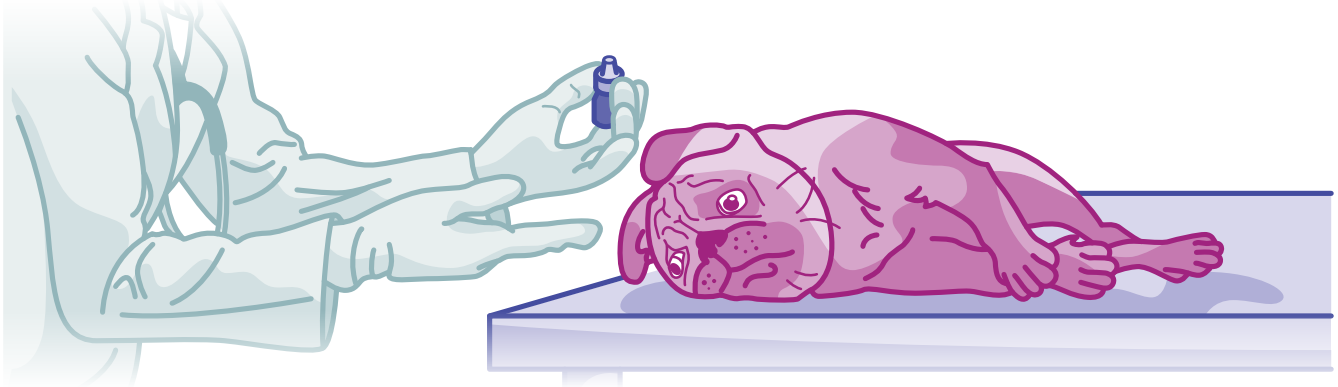
Physical injuries, chemical exposure and biological agents like bacteria and viruses can disrupt the superficial layers of the cornea. This is very painful, often causing the pet to rub and scratch at their eyes and worsen the trauma. Injury to the cornea also allows secondary infection to occur. Bacterial activity and the resulting inflammatory response can sometimes lead to a "melting ulcer." Without treatment, melting ulcers become progressively deeper until the inner membrane is at risk of rupturing. Rupture and infection of the interior of the eye can be difficult to treat. It may even lead to the need for surgical removal of the eye.



CLAIM OF THE MONTH

CORNEAL ULCER AND ENTROPION

Continued...



TREATMENT

Along with antibiotic eye drops, lubrication and pain relief, Jack also needed three surgical procedures. The first two were left and right blepharoplasty – surgical treatment to correct the inward rolling of the eye lids and prevent ongoing damage. The third surgery was a conjunctival graft. In this procedure, the soft tissue surrounding the eye was sutured across the corneal ulcer to provide protection and additional blood supply while the cornea took it's time healing.

CLAIM OUTCOME

Pets Plus Us pack member Jack needed \$3, 083.11** in specialized veterinary care for his entropion and corneal ulcer.

His human was reimbursed \$2, 266.49 through their Pets Plus Us Accident and Illness More plan.

We wish you a speedy recovery, Jack!

*Pet's name was changed for privacy

**Source: 2022 PTZ Insurance claims data. Value of claims in \$ CAD.

